

ANIMAL HEALTH SURVEILLANCE

Information contributed by staff of the Livestock Health and Pest Authorities and the NSW Department of Primary Industries

Foot-and-mouth disease exclusion near Wagga Wagga

Five of 64 steers died with suspected pneumonia caused by *Pasteurella multocida* after arrival at a property near Wagga Wagga.

They had been purchased 1 month earlier from a variety of owners and saleyards and were fed in a grassy paddock and supplemented with a combination of hay and grain that was very dusty and contained rough stalks. Surprisingly, they were eating this dusty, spiky feed despite the availability of pasture.

When the herd was examined by the district veterinarians, the first sign seen in the rest of the mob was the high number of steers showing excess salivation despite appearing very healthy.

One steer was down and reluctant to move. It had a fever, as well as many small, circular lesions in its mouth.

In a sample of the rest of the mob, two other steers had mouth lesions similar to those of the downer steer, and two were scouring. The emergency disease hotline was contacted and advised of the situation. Samples were taken for foot-and-mouth disease exclusion, although the risk of foot-and-mouth disease was not considered high.

The mob was prevented from gaining access to the feeder, and 8 hours later the drooling of saliva had stopped.

It was concluded that the dry, dusty,

spiky feed had been the main cause of the drooling, rather than the mouth lesions.

The recumbent steer died, and post-mortem examination revealed acute fibrinous pneumonia as well as a swollen carpus on the left front leg, with excess yellow fluid in the joint and tendon sheath.

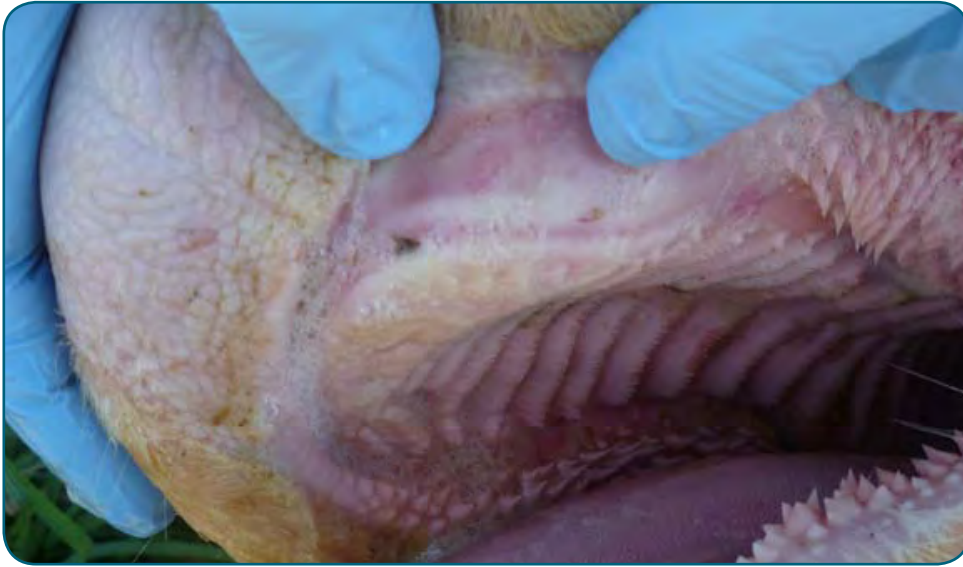The histopathologist reported a severe haemorrhagic pleuropneumonia consistent with infection with *Pasteurella* spp. Culture of the lungs and joint was unproductive; this was not unexpected, as the animal had been treated with antibiotics earlier.

Samples from mouth lesions in the salivating animals tested negative for foot- and-mouth disease and vesicular stomatitis viruses. Histopathology of a tongue lesion showed epithelial degeneration, hyperplasia and intracytoplasmic inclusions strongly suggestive of bovine papular stomatitis virus infection.

A range of samples for serology tested negative for pestivirus, malignant catarrhal fever and infectious bovine rhinotracheitis. However, five of five serum samples were moderately positive to chlamydial antibodies; this, when combined with some of the post-mortem and clinical signs in the animal that died, suggested that the underlying problem and cause of deaths may have been sporadic bovine encephalitis. More likely, the very dusty feed and recent transportation and stress may have

In this issue!

Foot-and-mouth disease exclusion near Wagga Wagga	1
Sheep deaths in a central NSW feedlot	2
Gobblers give up the ghost: not avian influenza	2
Evaluation of animal disease surveillance in New South Wales	2
Mother-of-millions toxicity in pregnant cattle	4
Hendra virus case studies	4
Lungworm in cattle	5
A case of abortion in cattle due to infection with <i>Salmonella chester</i>	5
Extra legs in Angus calves	6



The faint circular lesions are caused by bovine papular stomatitis virus. Photo: T Morton and H McGregor

been the predisposing cause of an ongoing pneumonia outbreak.

The herd was given access to more palatable hay, and any unwell steers were treated with oxytetracycline. The deaths ceased.

For more information contact Tony Morton or Helen McGregor, District Veterinarians, Hume Livestock Health and Pest Authority, on (02) 6923 0903.

Sheep deaths in a central NSW feedlot

A sheep feedlot in the Forbes area had 10 deaths in a mob of 400 pregnant, 1-year-old ewes. Scouring preceded the early deaths, but drenching the sheep for worms had made no difference. The ewes were being fed on a mix of lupins and barley and a small amount of stubble hay.

At necropsy of a recently deceased animal there was severe inflammation of the mucosal surface of the abomasum and small intestine. The mesenteric lymph nodes were enlarged and there was moderate colon inflammation. Although there were no characteristic 'tiger stripes' of inflammation in the intestine, samples were taken to exclude peste des petits ruminants, which is an exotic disease of small ruminants in northern Africa, the Middle East and India. Culture of intestinal contents did not isolate an infectious cause.

PAGE 2

The small intestine contained a moderate burden of *Trichostrongylus* worms.

Histopathology showed marked mucosal and submucosal congestion in the abomasum and small and large intestines. It was suspected that a low-grade grain poisoning was affecting the ewes. When the grain portion was reduced and antibiotics were given to individual animals they improved, and there were no more losses.

For more information contact Belinda Edmonstone, District Veterinarian, Lachlan Livestock Health and Pest Authority, on (02) 6852 1688.

Gobblers give up the ghost: not avian influenza

Fowl cholera killed 40 of 50 turkeys over a 2-week period in a mixed free-range flock of 500 turkeys, ducks, guinea fowls and chickens. There were no significant clinical signs beforehand.

At veterinary examination, only two older turkeys were showing signs of illness. The birds were 'fluffed up' and depressed and had swollen nose wattles. Post mortem examination was conducted on these two birds; the findings were unremarkable and the birds were in good body condition at the time.

Avian influenza and Newcastle disease were both excluded by PCR testing at the laboratory.

Histopathology showed the liver to have multifocal loss of hepatocytes with fibrin exudation and infiltrates of heterophils and mononuclear cells. A pure growth of *Pasteurella multocida* was grown from bacterial culture of a liver sample.

The affected turkeys were treated with antibiotics and procedures for rodent control and burning dead birds implemented.

For further information contact Colin Peake, District Veterinarian, Riverina Livestock Health and Pest Authority, Hay, on (02) 6993 3497.

Evaluation of animal disease surveillance in New South Wales

In February 2010, the Animal Biosecurity Unit initiated a national review of the effectiveness of animal disease surveillance in Australia, especially to see if the resources were placed where the highest disease risks are.

Australian experts coordinated by DAFF (the Federal Department of Agriculture, Forestry and Fisheries) have completed some draft, preliminary studies. We report them here to demonstrate their methodology, although their refinement is ongoing and the data presented here should be regarded merely as examples.

First, we chose a range of diseases, including foot-and-mouth disease, Japanese encephalitis, rabies, Hendra virus and classical swine fever, and we individually mapped the relative risk of an outbreak and spread of each disease. Map 1 shows the relative risks of entry, establishment and spread for foot-and-mouth disease. The highest risk areas are red, followed by yellow, green, light blue and blue in order of declining risk.

We then amalgamated the data for each disease and produced a 'surveillance risk map' (Map 2) in which the colour differences represent different relative risk. Livestock density and high stock-movement patterns are obvious contributors to risk, as are weather patterns and proximity to ports. The yellow areas in the map are 10 times less risky than the red

areas, and the green areas are 100 times less risky than the red areas.


The next step was to see whether our field disease surveillance resources were located where the biggest risks are.

The locations of LHPA and NSW Department of Primary Industries veterinary officers were mapped and overlaid, with a buffer of 100 km around each location. This demonstrated that all of the high-risk areas and virtually all of eastern NSW are within 100 km or 90 minutes' drive of a government veterinary officer (see Map 2).

We then asked the question: do the actual disease investigations by staff reflect effort where the most risk is? Our laboratory records were used as a proxy for all investigations by district and departmental veterinarians, and about half of the investigations (6000) over a 2-year period were able to be located to specific map co-ordinates.

The disease investigations conducted in NSW were predominantly in the eastern half of the State, corresponding to the areas with higher rainfall that have higher stocking densities (Map 3).

Fewer investigations were conducted in the Far West of the State (remember, though, that this is only part of the total amount of surveillance data). Other areas with few, or no, investigations corresponded to national parks, other reserves or the drier large-scale cropping regions.

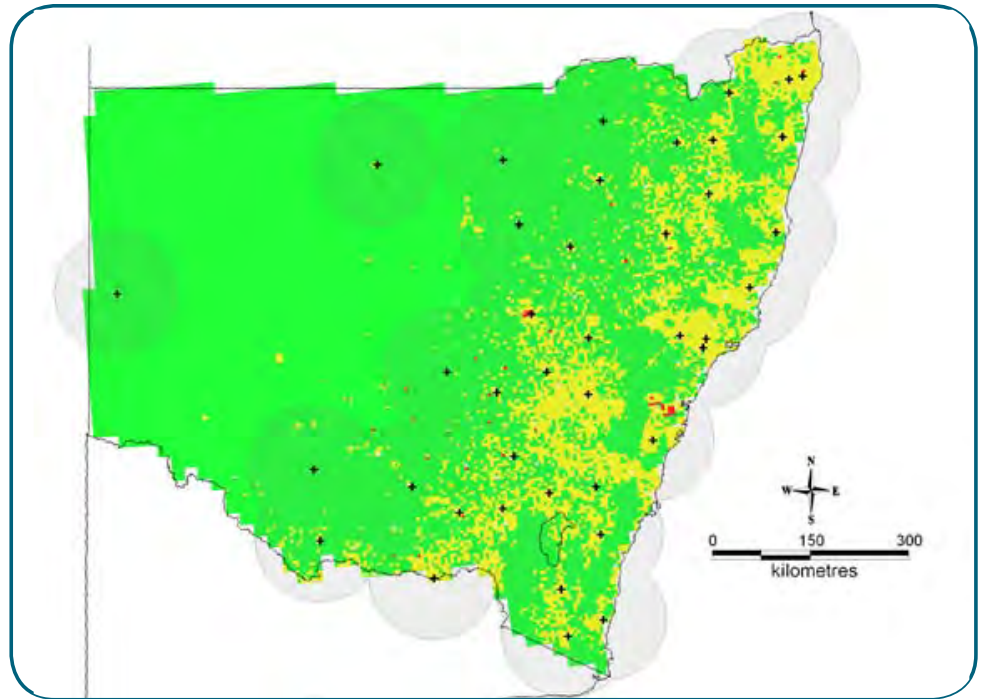


Map 1. Relative risks of foot-and-mouth disease in south-east Australia.
Map courtesy of Iain East.

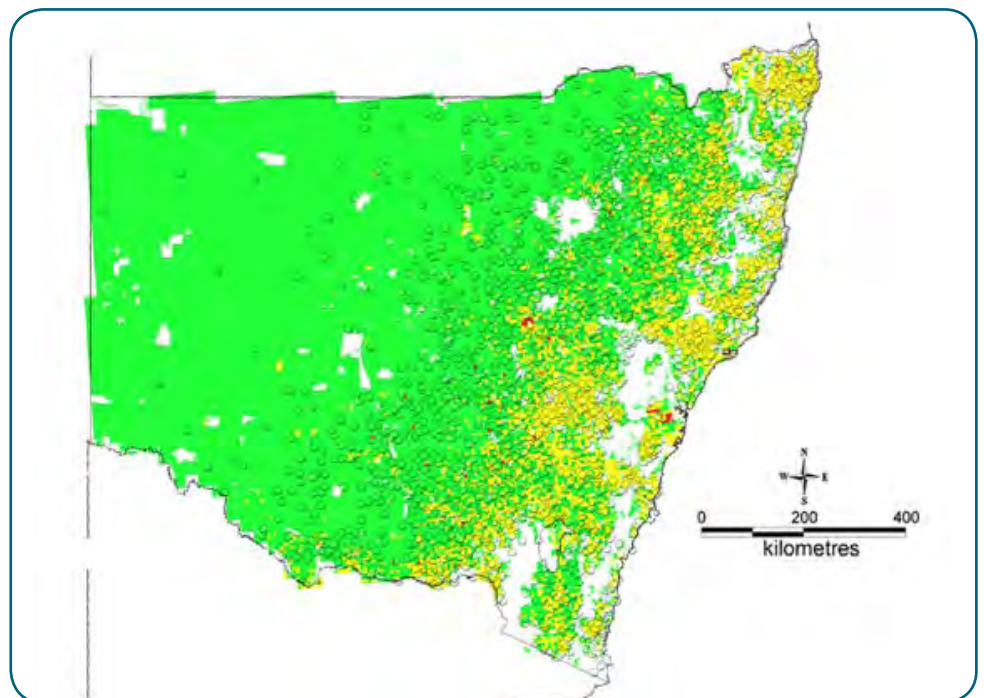
The purpose of this work is to contribute to a much more rational allocation of animal disease surveillance resources across Australia, and to find any gaps. The specialist epidemiology work behind these 'simple' maps is quite outstanding and that, in itself, is an important component of Australia's animal disease surveillance

expertise. The findings will be formally published at a later date.

For further information contact Rory Arthur, Manager Animal Biosecurity Surveillance and Epidemiology, NSW DPI Orange, on (02) 6391 3608.



Map 2. Risky areas for emergency disease surveillance overlaid with the locations of LHPA or NSW Department of Primary Industries field officers (shown by crosses). (Some data are missing.) Map courtesy of Iain East.



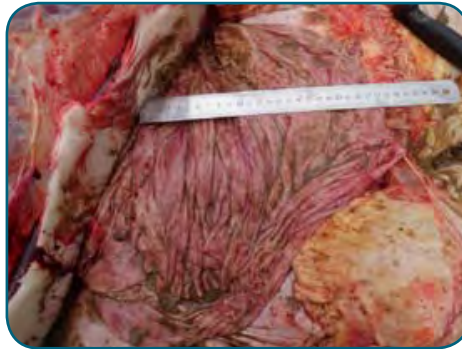Map 3. Field investigations were in the highest-risk areas. White areas are parks, reserves and prohibited areas from which domestic animals are excluded.
Map courtesy of Iain East.

Mother-of-millions toxicity in pregnant cattle

Five of 100 Hereford cows died from mother-of-millions toxicity on a property east of Narrabri.

Clinical signs included dehydration, depression, profuse, dark brown/black watery diarrhoea, sham drinking and anorexia. One cow was reluctant to move with the mob, and when pressured she became excited and dropped dead. There were numerous haemorrhages in her abomasum and her lungs were mildly congested. There was about twice the normal amount of pericardial fluid and haemorrhages were visible in the heart muscle.

The paddock from which the cows were moved consisted of dry, standing native grass pasture. In a wooded area extending in a strip approximately 20 m wide along the boundary fence there were a large number of mother-of-millions plants in early flower. Many of the plants had been chewed off, and a diagnosis of mother-of-millions plant toxicity was made.



Numerous haemorrhages in the abomasum of a pregnant cow with mother-of-millions toxicity. Photo: L. Read



Mother-of-millions plants in early flower in the paddock. Photo: L. Read

The producer minimised any stress on the mob over the next 3 weeks to reduce deaths. The area infested with mother of millions plants was treated with a herbicide and permanently fenced off from the paddock.

Mother-of millions (*Bryophyllum* spp.) is native to Madagascar. It is a popular garden plant in eastern Australia, especially in the drier, inland areas. *Bryophyllum* spp. contain cardiac glycosides of the bufadienolide type. These toxins cause heart arrhythmias leading to ventricular fibrillation and arrest. The flower heads contain five times as much toxin as the stems and leaves. Fatally affected animals die between 5 days and 3 weeks after the start ingesting the plant.

For further information contact Libby Read, District Veterinarian, North West LHPA, Narrabri-Walgett, on (02) 6792 2533.

Hendra virus case studies

In July–August the North Coast of NSW had seven properties on which Hendra virus was diagnosed. The following two cases are examples that emphasise the importance of laboratory diagnosis.

A cattle producer near Lismore had a horse that had died with its head stuck through a wire fence. The horse had shown no signs of disease 12 to 18 hours earlier. It was in a paddock containing a fig tree. Flying foxes were suspected to visit the property but were not thought to be common. A private veterinarian indicated that it was unlikely to be Hendra virus but advised the producer to contact the LHPA. After collecting a history from the farmer, two district veterinarians from the LHPA independently considered that the case was likely to be an accident. Despite this, a district veterinarian attended the farm to investigate.

The dead horse was observed by the district veterinarian with its head and neck through a fence line at the bottom of a hill. The head and neck were on the ground underneath the bottom fence wire. Another horse was in the paddock with no signs of disease. Using appropriate

personal protective equipment, the veterinarian took oral and nasal swabs from the horse. It was noted that there was a substantial amount of blood-stained froth in the nasal cavities. Swabs were placed in PBGS (phosphate-buffered gelatine saline containing antibiotics) viral transport medium.

Both the oral and the nasal swabs were positive for Hendra virus on an N Gene TaqMan assay done at the AAHL (Australian Animal Health Laboratory) and on a PCR test done at the NSW EMAI (Elizabeth Macarthur Agricultural Institute) State Veterinary Diagnostic Laboratory. Testing on a companion horse was negative.

Meanwhile, a neighbour to a sugarcane property near Ballina reported two dead horses in their absent neighbour's paddock. Wearing appropriate personal protective equipment, the district veterinarian attended the property. One dead horse was attached to a fence wire. A D-clip on its headstall had ensnared the wire.

The other horse was dead in the middle of the lawn near the house. It appeared to have prolapsed and had decomposing tissue exuding from both rear orifices. The house paddock contained some native trees and an old orchard. Four live horses were observed without any obvious signs of disease. The provisional field diagnosis by the district veterinarian was an accident

in the case of the horse attached to the fence and a reproductive incident in the case of the other horse. Swabs and jugular blood were collected from the dead horses. All samples collected from the horses were positive for Hendra virus on testing done at both the NSW State Veterinary Diagnostic Laboratory and AAHL.

These case studies demonstrate the following:

- Some cases of Hendra virus, especially mortalities, will be diagnosed only if a government field service is available to attend.
- Hendra virus should be suspected in horses stuck to, or through, a fence.
- The use of swabs to collect a range of fluids from a dead horse appears satisfactory to detect positive field cases of Hendra virus.

Horse owners should be advised that if they find a horse stuck in a fence then they should not assume that this is the result of an accident. The neurological damage done by Hendra virus may predispose horses to becoming caught in fences.

For further information contact Matt Ball, Senior District Veterinarian, North Coast LHPA Lismore, on (02) 6621 3217.

Lungworm in cattle

A North Coast cattle herd of three cows and four weaners experienced ill thrift, respiratory disease and death due to the lungworm *Dictyocaulus viviparus*.

The cattle were grazing with sheep and alpaca on short, green pasture in a single paddock. Each of the weaner cattle was underweight, and two had deep 'chesty' coughs. One weaner died and was necropsied.

It was in very poor body condition and had fat necrosis. There was a heavy *Dictyocaulus* burden in the bronchi, with focal areas of collapse and hepatisation of the lungs. There was also mild pleurisy and a moderate *Oesophagostomum radiatum* burden in the intestines.

The cattle were treated with an anthelmintic, and oxytetracycline was provided to treat two cattle that showed signs of pneumonia following treatment. Dead and dying lungworms in the airways can initiate a 'foreign body' bronchopneumonia.

For further information contact Phil Kemsley, District Veterinarian North Coast Livestock Health and Pest Authority, Casino, on (02) 6662 3166.

A case of abortion in cattle due to infection with *Salmonella chester*

Thirteen cows of a mob of 80 aborted in the Narrabri district in July. They had been vaccinated against pestivirus, leptospirosis and clostridial disease some months earlier. The cows that had not aborted appeared normal. Eight cows that had aborted and two aborted calves were examined. The cows had retained foetal membranes and elevated temperatures. The aborted calves appeared normal, although one may have had an enlarged liver. Samples were taken for laboratory examination, and brucellosis and trichomoniasis were excluded.

Histopathology on the liver of one calf showed a hepatopathy consistent with *Salmonella* or *Campylobacter* infection. Nothing was cultured from the fresh



This Hendra-virus-affected horse had become attached to the fence. Photo: M. Ball

stomach contents of this calf. A wide range of fresh and preserved samples from the other calf were negative for leptospirosis, neosporosis and pestivirus, but culture of the fresh stomach contents was positive for *Salmonella chester*.

Serology on the cows suggested that the herd had recently been exposed to pestivirus as well as to *Salmonella* spp. The evidence suggested that exposure to *S. chester* was the most likely cause of the abortions. Unfortunately a clear source could not be identified; the cattle were moved to another paddock and calving proceeded normally.

Of the *Salmonella* organisms known to occur in cattle and cause disease, *S. chester* is relatively unknown.

For further information contact Ted Irwin, District Veterinarian, North West Livestock Health and Pest Authority, on (02) 6729 1528.

Extra legs in Angus calves

Polymelia is the condition of being born with one or more extra limbs. If the limb or limbs are attached to the vertebral column, this is called notomelia.

The incidence of notomelia seems to be increasing in Angus calves in Australia above the sporadic background level, suggesting the possibility of an emerging heritable defect in this breed. At least 15 cases of notomelia have been reported in newborn Angus calves in NSW in the last 2 years.

One purebred commercial Angus herd with an increased incidence of other genetic disorders from line breeding (i.e. mating animals that are closely related genetically, in this case animals with a propensity for high fat marbling in muscle) has also experienced several cases of notomelia in each of the last two calving seasons. The clustering of notomelia cases in this linebred herd suggests the possibility of an underlying heritable cause for notomelia in Angus calves.

NSW veterinarians who see polymelia cases in Angus calves should contact their local

LHPA veterinarian or Dr Laurence Denholm of the NSW Department of Primary Industries and encourage the owners to participate in finding the cause.

Trial breeding can identify patterns of inheritance, and Dr Denholm is seeking further polymelia cases – particularly affected Angus heifer calves – to interbreed to determine the heritability of this congenital defect.

Laboratory analysis of the DNA of these calves is also likely to reveal any genetic changes associated with this condition. Samples from affected calves have been sent to a laboratory in the USA to look for any changes in their DNA compared with the DNA of calves without the condition. The laboratory, however, needs additional DNA samples from cases of polymelia to make progress in this research. The aim is to develop a diagnostic DNA test to detect carriers. The test can then be used to prevent further spread of the defect, as has been achieved with other genetic defects in recent years.

Variants of polymelia are classified according to the point of attachment to the body: *notomelia* where the attachment is in the region of the embryonic notochord; *cephalomelia* where the attachment is on the head; *thoracomelia* where the attachment is on the thorax below the dorsal midline; and *dipygus* or *pygomelia* where the attachment is to the pelvis. The majority of bovine polymelia cases are notomelic.

The foot of the supernumerary limb may be normal or the digits may be fused (syndactyly). Minor bone abnormalities in these extra limbs are also common, including fusion of the bones at the shoulder and elbow. Thin bands of muscle may or may not be seen embedded in abnormally large amounts of fat on dissection of the limb.

Some of the calves have more than one, and up to four, complete supernumerary limbs; others have a single additional limb but with abnormal bifurcations at a level below the shoulder joint, sometimes creating the appearance of multiple limbs.

The economic effects of the polymelia condition are related to the management of difficult births and the cost of surgery to remove the extra limbs. In many polymelia cases the additional limbs interfere with birth of the affected calf, leading to death of the calf and even death of the mother cow.

After birth, in some cases the supernumerary limbs remain small and the affected calves appear to grow and breed normally, regardless of whether or not the extra limbs are surgically removed. In other cases the supernumerary limbs grow in proportion to the animal and become quite large, interfering with walking and with normal life – a significant animal welfare issue.

Developmental anomalies of the limbs are among the most common congenital defects in humans and domestic animals and are more frequent in the lower limbs. The subcellular molecular processes in the developing embryo that lead to polymelia are, however, not well understood at this time.

True polymelia apparently results from a failure in the normal regression of the supernumerary primordial limb buds in the mesodermal layer of the developing embryo; hence one or more supernumerary limbs (or parts of limbs) arise from continued development of these persistent vestigial limb buds. Normally, the supernumerary limb buds regress early

in embryonic development from localised intercellular signals that stop expression of the genes required for further limb growth, but this seems to fail in the case of polymelia.

In *Drosophila* flies, mutations of the *slimb* gene are known to cause supernumerary limbs because the gene loses its capacity to regulate the transcription of genes involved in local control of the cell cycle in cells of the supernumerary limb buds. This control is needed for the normal cessation of further cell growth and replication and hence for further development in the supernumerary limb buds.

A similar gene known as the β -TrCP gene exists in mammals, but its functions in mammalian embryonic development are currently unknown. However, there is some evidence of β -TrCP involvement in biochemical pathways similar to those of *slimb* that regulate the cell cycle – and hence cell replication – to effectively inhibit further cellular development at specific locations, including in the supernumerary limb buds. It may be that mutation of this β -TrCP gene, or another related gene in the same embryonic biochemical pathway, blocks the normal local controls on cell development and replication in the calf's supernumerary limb buds – i.e. the controls that prevent polymelia from developing in normal calves.

Despite the evidence for a heritable basis to polymelia in Angus cattle, alternative causes are possible but do seem unlikely on epidemiological grounds, particularly given the apparent breed predisposition and the wide geographic distribution of these recent polymelia cases.

For example, tadpoles of several frog species develop extra legs when infected with parasitic species of the trematode *Riberoia*, particularly when the tadpoles have also been exposed to environmental toxins such as organochlorine pesticides. Vitamin A toxicity also causes supernumerary hind limbs to develop in frogs. The toxicity and the parasitic infection may simply interfere with the same intercellular signalling pathway in early embryonic development and thereby produce the same developmental abnormality as is seen with a heritable mutation of one of the genes involved in this signalling pathway. By affecting the same developmental pathway, quite different environmental factors and genetic mutations can produce an identical developmental defect such as polymelia.

The NSW contributors to this project are Dr Laurence Denholm (NSW DPI), Lisa Martin (New England Livestock Health and Pest Authority), Andrew Denman (Blayney Veterinary Hospital) and Professor Peter Windsor (University of Sydney). The collaborating genomics laboratory in the USA is led by Associate Professor Jonathan Beever of the University of Illinois and AgriGenomics Inc. His laboratory has identified the mutations in the genes that code for many heritable defects in cattle, including the mutation that causes congenital 'curly calf' syndrome in Angus cattle (arthrogryposis multiplex), which was reported in *Animal Health Surveillance 2008/3*.

For further information contact Dr Laurence Denholm, NSW DPI Orange, on (02) 63655482, or lauriedenholm@industry.nsw.gov.au.



An Angus calf with polymelia. Photo: L. Denholm

Getting information on animal diseases

This surveillance report can convey only a very limited amount of information about the occurrence and distribution of livestock diseases in New South Wales. If you would like more specific information about diseases occurring in your part of the State, contact your local Livestock Health and Pest Authorities District Veterinarian or Departmental Regional Veterinary Officer.

For Statewide information, contact the NSW Department of Primary Industries Animal and Plant Biosecurity Branch in Orange on (02) 6391 3237 or fax (02) 6361 9976.

For more information on national disease status, check the National Animal Health Information System (NAHIS) via the internet at:
<http://www.animalhealthaustralia.com.au/status/nahis.cfm>

This is a report under the Animal Disease Surveillance Operational Plan, Project 8, 'Reporting for Animal Disease Status in NSW'.

Prepared by Rory Arthur, Animal and Plant Biosecurity Branch,
NSW Department of Primary Industries, Kite St, Orange 2800.
Phone (02) 6391 3806

E-mail: rory.arthur@industry.nsw.gov.au

Copies of NSW Animal Health Surveillance reports are available on the internet at:
<http://www.dpi.nsw.gov.au/newsletters/animal-health-surveillance>

Disclaimer

The information contained in this publication is based on knowledge and understanding at the time of writing (October 2011). However, because of advances in knowledge, users are reminded of the need to ensure that information upon which they rely is up-to-date and to check the currency of the information with the appropriate officer of NSW Department of Primary Industries or the user's independent adviser.

The product trade names in this publication are supplied on the understanding that no preference between equivalent products is intended and that the inclusion of a product name does not imply endorsement by the NSW Department of Primary Industries over any equivalent product from another manufacturer.



Department of
Primary Industries



LIVESTOCK HEALTH AND PEST AUTHORITIES

LHPA
Safeguarding Agriculture in NSW